

Original article:

Prevalence of Rectus sternalis: A Clinical Enigma

Dr.Muthu Prasad Puthuraj¹, Dr.Sumathi Shanmugam²

¹-Assistant Professor, Department of Anatomy, Government Thiruvavur medical College, Thiruvavur

²- Assistant Professor, Department of Anatomy, Thanjavur Medical College, Thanjavur.

Corresponding author: Dr.Muthu Prasad Puthuraj

Abstract:

Background: Rectus sternalis is an anatomical variant found in the anterior thoracic wall, familiar to anatomists but relatively unknown to clinicians. The situation of this muscle may be sternal or parasternal with wide variations in its superior and inferior attachments. Recent advances in imaging techniques have brought this muscle into clinical significance.

Aims & Objectives: The prevalence rate of Sternalis was estimated in the eastern delta region of Tamil Nadu by looking for rectus sternalis during routine dissection of thirty cadavers.

Results: Rectus sternalis was present in one male cadaver aged sixty years. The muscle was superficial to the fascia covering left Pectoralis major. The lower part of the muscle was fleshy and was observed to be arising from the upper part of rectus sheath and from 6th, 7th and 8th costal cartilages. The upper end of the muscle was tendinous and was inserted into the upper end of sternum and 3rd and 4th costal cartilages. The muscle measured 14 cms in length and 3.5 cms in breadth at the lower part. The prevalence of rectus sternalis in the present study was 3.3%.

Discussion: The reported prevalence of rectus sternalis is 4-8% in the cadaveric studies. Rectus sternalis is frequently associated with axial anomalies and abnormalities of Pectoralis major. Nerve supply from either the pectoral nerve or intercostal nerve determines its embryological origin from either Pectoralis or Rectus abdominis.

Conclusion: A clinician's familiarity with this rectus sternalis muscle may avoid unnecessary invasive procedures and undue stress to the patient.

Keywords: rectus sternalis, supernumerary muscle, clinical significance.

Introduction

Rectus sternalis is an anatomical variant found in the anterior thoracic wall. It is a supernumerary muscle familiar to anatomists but relatively unknown to clinicians. Its formal description was first made by Dupuy in 1726 though it had been demonstrated by Bartolimen Cabrolius, a French surgeon in 1604 itself. There are a dozen different names being used to describe the muscle – Musculus sternalis, episternalis, parasternalis, presternalis, rectus sterni Thoracicus, rectus thoracis, rectus thoracicus superficialis, sternalis brutorum and Japonicas which can be attributed to its different morphological presentations. Although it has been described as early as 17th century its

innervations and development are not yet well established.⁽¹⁾

The overall incidence of sternalis muscle among Indians is 4-8% with wide differences in prevalence among various ethnic races. The variations in morphology and attachments are attributed to the geographical variability in prevalence rates.⁽²⁾ Reported incidences in various ethnic groups range from 2.3 %⁽¹⁾ to 6.4% in Europeans, 1%⁽⁴⁾ to 13.1 % in Asians and approximately 11% in Africans.⁽³⁾ The average prevalence is 11.5% in Asians. Asians by themselves show a wide range of prevalence with Chinese reporting 23.5% and Taiwanese 1%.⁽⁴⁾ The unilateral occurrence is twice as common with a

prevalence of 4.5% and is more common on the right side. ⁽⁵⁾ It has a slightly higher frequency among women(8.6%) than men(7.5%) which can be attributed to the higher rates of medical imaging and surgery of anterior thoracic wall for breast related conditions in females. ⁽⁶⁾

Rectus sternalis is a small longitudinal strip of muscle present in the anterior thoracic wall that lies superficial to pectoral fascia overlying the pectoralis major. The situation of this muscle may be sternal or parasternal with wide variations in its superior and inferior attachments. The origin of rectus sternalis is either from the lower ribs, lower end of sternum, rectus sheath or external oblique aponeurosis which courses upwards and is inserted into either the upper ribs, upper part of sternum or sternocleidomastoid muscle. ⁽⁷⁾ The nerve supply to rectus sternalis muscle is derived either from pectoral nerves(55%) or intercostal nerves(43%) or both(2%) which has paved way for several hypotheses regarding its embryological origin. ⁽⁸⁾

Recent surge in medical imaging and surgical procedures has brought this sternalis muscle into relevance in clinical practise. The unawareness about this muscle among the clinicians reflects on the imaging reports of the advanced imaging techniques describing this obscure rectus sternalis as focal densities on mammography leading to suspicion of malignancy resulting in unnecessary invasive procedures and undue stress to the patient. ^(9,10)

Aims & Objectives:

The objective was to estimate the prevalence of rectus sternalis in people of eastern delta region of Tamilnadu and to analyse and compare the observations with its prevalence in other ethnic population.

Materials & Methods:

The present estimation was carried out on thirty formalin fixed adult cadavers over a period of three

years in the Department of anatomy. Twenty four male cadavers and six female cadavers used for first year dissection classes were taken up for the study. Routine dissection of Pectoral region were performed as per Cunningham`s practical manual. The presence of muscular variations in the paramedian region of anterior thoracic wall was looked for to record its origin, insertion, nerve supply and morphological features. The length and breadth of the muscle was also measured using a thread, scale and marker. The prevalence rate was estimated.

Observations and Results:

Among the thirty specimens, the presence of rectus sternalis was observed in one male cadaver aged around sixty years. The rectus sternalis was placed almost vertically along the left paramedian region. The muscle was superficial to the left Pectoralis major muscle and situated between the superficial fascia of the anterior thoracic region and pectoral fascia. The lower part of the muscle was fleshy and was observed to be arising from the upper part of rectus sheath and from 6th, 7th and 8th costal cartilages. The upper end of the muscle was tendinous and was inserted into the upper end of sternum and 3rd and 4th costal cartilages.(Fig:1a) The muscle measured 14 cms in length and 3.5 cms in breadth at the lower part. It was innervated by the left 4th intercostal nerve.(Fig:1b) The incidence of rectus sternalis in the present study was 3.3%.

Discussion:

The prevalence of rectus sternalis on an average is 4-8% in the cadaveric studies. Advancements in soft tissue imaging and its routine use have led to frequent discovery of rectus sternalis in living humans. The multidetector computed tomography scans record a prevalence rate of 6.4% which is similar to the cadaveric study reports. ⁽¹¹⁾ Retrospective studies of operative case records of patients who underwent breast surgeries

including augmentation procedures report 0.7% to 0.3% occurrence of rectus sternalis.^(12,13) The variant morphological presentations of this muscle is considered to be the reason for the wide range of prevalence rate.

Phylogenetic origin:

Albinus in 1734 was the first to propose that sternalis is connected with rectus abdominis muscle and this view was supported by many in the 17th and 18th centuries. It was later described that rather than being associated with rectus abdominis its more often associated with External oblique aponeurosis. There were many others who believed it was a downward extension of Sternocleidomastoid muscle as it was closely associated with clavicle and upper part of sternum. Turner has suggested its association with panniculus carnosus on the basis of his comparative studies on animals. He describes that rectus sternalis represents a vestige of the cuticular muscles of mammals that is largely present on their trunk. This view was supported by Charles Darwin (1871) in his book "The Descent of man". Rectus sternalis is frequently associated with axial anomalies and abnormalities of Pectoralis major.⁽¹⁴⁾ Rectus sternalis was observed in nine anencephalic fetuses.^(15,16) Harper reported three anencephalic fetuses with rectus sternalis. The coexistence of rectus sternalis in anencephaly is nearly 50%.⁽¹⁷⁾ Incomplete development of sternal head of Pectoralis major is commonly associated with rectus sternalis.^(8,18)

Attachments:

Rectus sternalis may be unilateral or bilateral with variable attachments. This muscle when typical arises from the sheath of the rectus abdominis, costal cartilages of lower ribs, aponeurosis of the External oblique muscle and ends above on to the upper costal cartilages, manubrium or may be joined to the sternal head of sternocleidomastoid

muscle.⁽¹⁹⁾ The length of the muscle usually ranges between 2.4 cms to 26 cms and its width 0.48cms to 7 cms with a varied presentation.

Classification:

Morphologically Jelev classified and grouped the muscle primarily into unilateral (Type I) and bilateral (Type II). There are subclassifications (1,2,3 and 4) in each type based on the number, symmetry of muscle bellies and relation to other muscles. (Illustration-1). The rectus sternalis in the present observation belonged to Type I(1).

Nerve Supply:

The nerve supply to rectus sternalis is variable. Hallett attributed the innervation of rectus sternalis to 3rd, 4th and 5th intercostal nerves.⁽²⁰⁾ This view was acknowledged by Shen et al, 1992; O'Neil & Folan, 1998; Jelev, 2001; Saeed, 2002; Motabagani, 2004; Georgiev, 2009.⁽¹⁴⁾ Cunningham and Shepherd traced and substantiated the innervation of rectus sternalis by Medial Pectoral nerve.^(21,16) This was supported by Wallace, 1886; Ingalls, 1913; Patten, 1934; Harper, 1936; Kida et al, 2000; Kumar et al, 2003.⁽¹⁴⁾

According to Barlow, on a literature review of 146 rectus sternalis cases reported by 17 authors rectus sternalis was supplied by pectoral nerve in 68.5% and Intercostal nerve in 26.7% and a combination in 4.8%.⁽³⁾ O'Neill on reviewing 191 rectus sternalis cases reported by 34 authors found 55% of rectus sternalis were innervated by branches from the pectoral nerve and 43% by branches from intercostal nerves and 2% by a combination of both.⁽⁸⁾ Dual innervation is rare [2%] and has last been reported by Mori in 1964. Eisler doubted both dual innervations and innervations by the intercostal nerve. According to him rectus sternalis received innervations only from the pectoral nerve and the intercostal nerves only perforate the rectus sternalis muscle.⁽²²⁾ Saed et al⁽²³⁾ emphasises on the innervation of sternalis to describe the origin of the

muscle- sternalis is derived either from pectoralis major with innervation from the pectoral nerve or is derived from the rectus abdominis with its innervation from the intercostal nerve.

Development:

Though discovered in 17th century, the development of the muscle remains elusive. Based on the the attachment and innervations of rectus sternalis several theories regarding the embryonic origin of rectus sternalis have been proposed. Turner described it as a form of atavism corresponding to pectoral cutaneous of lower animals. According to Ruge it is a vestige of the cuticular muscle of mammals present subcutaneously in trunk.⁽¹⁴⁾ Barlow suggests that it represents the remains of panniculus carnosus.⁽³⁾ Cunninghams has described this variant as a displaced and rotated segment of pectoral muscle mass with a proneness for a range of morphological presentation.

The larger the displaced segment the larger the deficit and larger the sternalis muscle. As these displaced segments migrate from their normal course they tend to make connections with sternal head of sternocleidomastoid superiorly and rectus abdominis inferiorly.^(21,24) Abraham P.S demonstrated rectus sternalis in six of eleven anencephalic foetuses. In all these cases the rectus sternalis was found to lie in the same plane as Pectoralis major and incidentally the medial part of pectoralis major was deficient. It's not yet clear whether prominent development of rectus sternalis prevents development of pectoralis major or deficiency of pectoralis major is compensated by the development of rectus sternalis.⁽¹⁴⁾ Sadler interpreted it as a part of the ventral longitudinal muscle column arising from the ventral tips of hypomeres.

It's phylogenetically suggested to be a remnant of longitudinal ventral paramedian muscle which also

gives rise to Rectus abdominis and Sternocleidomastoid.^(23, 25, 26)

Nerve supply from either the pectoral nerve or intercostal nerve determines its embryological origin from either Pectoralis or Rectus abdominis. Some authors describe that rectus sternalis is supplied by Pectoral nerve and suggest that the muscle is a derivative of Pectoralis major.⁽¹²⁾ Others were of the opinion that intercostal nerve supplies rectus sternalis and the muscle is a continuation of rectus abdominis.^(3,19) The present study demonstrates that the sternalis muscle is innervated by the 4th intercostal nerve. Thus the present study supports the opinion that the sternalis muscle is derived from the ventral longitudinal paramedian muscular sheet represented in humans by the strap muscles in neck, rectus abdominis in the abdomen and if present the sternalis in the thorax.

A clinician's familiarity with this rectus sternalis muscle may avoid unnecessary invasive procedures and undue stress to the patient. In breast and thoracic surgeries when undetected prior to surgery it can interfere with procedures leading to prolonged intraoperative periods.

In radiotherapeutic procedures the depth at which internal mammary nodes are irradiated will vary with the presence of this muscle. The rectus sternalis can also present alterations in ECG. It can be misinterpreted as a mass requiring surgery. When detected preoperatively it can be used as a flap in reconstructive surgeries related to breast and anterior thoracic wall and to improve the aesthetic results in breast augmentation surgeries by providing extra cover for the prosthesis.^(27, 28)

The present estimate of rectus sternalis muscle done on a sample of thirty cadavers shows a prevalence of 3.3%. The sternalis muscle with its variant origin and insertion and conflicting reports

on the nerves innervating the muscle highlights the need for further investigations and study in this area on a larger sample.

Figure: 1a



Figure: 1b

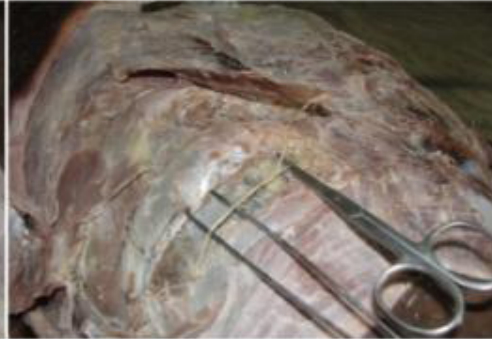

Figure: 1a- shows the Rectus sternalis on left side.

Figure: 1b- shows the Left 4th intercostal nerve supplying the Sternalis muscle.

Illustration: 1

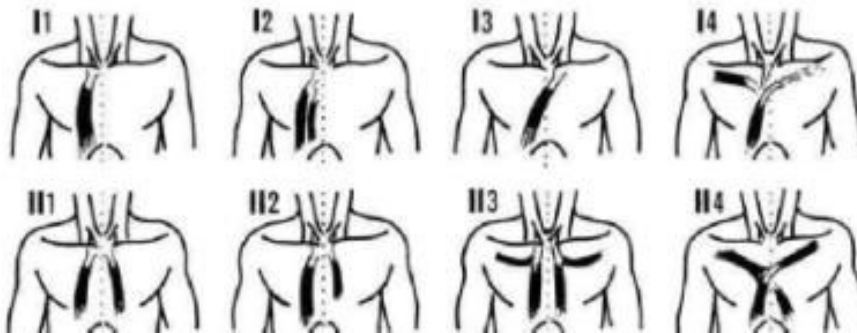


Illustration: 1- schematic drawing of the Jelev's classification of Types of Sternalis muscle.

Conclusion

The knowledge and awareness about the presence of this small obscure muscle is significant in performing diagnostic and interventional procedures related to the anterior chest wall. It may be mistaken for tumor on mammography and as a recurrence on follow up after radiotherapy. The

awareness of this muscle during breast surgeries will also help to identify the appropriate plane of dissection in mastectomy. Hence a clinician's familiarity with this muscle may avoid unnecessary procedures and complications.

References:

1. Turner WM. On the Musculus sternalis. *J Anat Physiol*, 1867; 1:246-253.
2. Hung LY, Lucachu DC, Wong JJ. Back to the debate: Sternalis muscle. *Int J Morphol*, 2012; 30(1):330-336.
3. Barlow RN. The Sternalis muscle in American whites and Negroes. *Anat Record*, 1935; 61(4):413-426.
4. Snosek M, Tubbs SR, Loukas M. Sternalis muscle: What every anatomist and clinician should know. *Clin Anatomy*, 2014; 27(6):866-884.
5. Bailey PM, Tzarnas CD. The sternalis Muscle: a normal finding encountered during breast surgery. *Plastic Reconstr Surg*, 1999; 103(4): 1189-1190.
6. Scott-Conner CE, Al-Jurf AS. The sternalis muscle. *Clin Anat*, 2002; 15:67-69.
7. Standing S, Borley NR, Collins P, Crossman AR, Gatzoulis MA, Healy JC et al. Pectoral girdle , Shoulder Region and Axilla, In: Gray`s Anatomy ,David Johnson and Harold Ellis (ed)., 39th ed.Churchill livingstone, Elsevier, Philadelphia.2005:834.
8. O`Neil MN, Folan-Curran J. Case report: Bilateral sternalis muscles with a bilateral Pectoralis major anomaly. *J Anat*, 1998; 193:289-292.
9. Kumar H, Rath G, Sharma M, Kohli M, Rani B. Bilateral sternalis with unusual left sided presentation: a clinical perspective. *Yonsei Med J*, 2003; 44:719-722.
10. Bradley FM, Hoover HC, Hulka CA, Whitman GJ, McCarthy KA ,et al. The sternalis muscle: an unusual normal finding seen on mammography. *Am J Roentgenol*, 1996; 166(1):33-36.
11. Young Lee B, Young Byun J, Hee Kim H, Mee Cho S, et al. The sternalis muscles: incidence and imaging findings on MDCT. *J Thorac Imaging*, 2006; 21(3): 179-183.
12. Harish K, Gopinath KS. Sternalis muscle: importance in surgery of the breast. *Surg Radiol Anat*, 2003; 25:311-314.
13. Khan UD. Use of rectus sternalis in augmentation mammoplasty: case report and literature search. *Aesthetic Plast Surg*, 2008; 32:21-24.
14. Michael Snosek and Marios Loukas. Thoracic wall Muscles. In: Bergman`s comprehensive encyclopaedia of Human Anatomic Variation. Shane Tubbs R, Mohammadali M Shoja, Marios Loukas (ed), John Wiley and Sons , Hoboken, New Jersey, 2016; 350-364.
15. Shepherd FJ .Musculus sternalis and its Nerve supply. *J Anat Physiol*, 1889; 23(2):303-307.
16. Shepherd FJ. The musculus sternalis and its occurrence in Human Anencephalous monsters. *J Anat Physiol*, 1885; 19(3):310-319.
17. Windle BC. The myology of the Anencephalous Foetus. *J Anat Physiol*, 1893; 27(3):348-353.
18. Kida MY, Kudoh H. Innervation of the sternalis muscle accompanied by congenital partial absence of the Pectoralis major muscle. *Okajimas Folia Anat Jpn*, 1991; 67(6):449-455.
19. Jeleu L, Georgiev G, Surchev L. The sternalis muscle in the Bulgarian population: classification of Sternales. *J Anat*, 2001; 199(3):359-363.
20. Hallett CH. Muscular system of the Human body. *Edinburgh Med surg J*, 1848; 69:1-31.
21. Cunningham DJ. The musculus sternalis. *J Anat Physiol*, 1888; 22(3):391-407.
22. Huntington GS. The deviation and significance of certain supernumerary muscles of pectoral region. *J Anat Physiol*, 1904; 39:1-68.
23. Saeed M, Murshid KR, Rufai AA, Elsayed SE, Sadiq MS. An anatomical variant of chest wall musculature. *Saudi Med J*, 2002; 23(10):1214-1221.
24. Clemente CD. Muscle and fasciae .In: Gray`s Anatomy, 30th ed, Philadelphia, Lea and Febiger, 1985
25. Sadler TW. Langmans Essential Medical Embryology. 12th ed, Lippincott Williams & Wilkin, Baltimore. 1995; 147.
26. Motabagani MA, Sonalla A, Abdel-Meguid E, Bakheit MA. Morphological study of the uncommon rectus sternalis muscle in German cadavers. *East Afr /med J*, 2004; 81(3):130-133.
27. Raikos A, Paraskevas GK, Maria Tzika, Pedro Faustmann, Stefanos Triaridis. Sternalis Muscle: an underestimated anterior chest wall anatomical variant. *J Cardiothorac Surg*, 2011; 6:73.
28. Britton CA. Sub pectoral mass mimicking a malignant breast mass on mammography. *Am J Roentgen*, 1992; 159:221.